SD-IAP 670

MUDr. Kristýna Pivovarčíková

Šiklův ústav patologie LF UK a FN Plzeň
Bioptická laboratoř s.r.o.

- Muž
- 70 let
- Pacient odeslán ambulantním urologem pro nález dilatace dutého systému pravé ledviny s megaureterem, při rozsáhlé nádorové infiltraci močového měchýře a prostaty
- TRUS prostaty vpravo prokazuje rozsáhlou infiltraci místy s rozpadovými dutinami
- CT - **Pokročilý tumor v močovém měchýři způsobuje městnání v obou ledvinách, infiltruje i prostatu**, nevyloučíme možnost primárního tumoru prostaty invadující močový měchýř. Generalizace do skeletu bederní páteře a pánve. Nevyloučíme generalizaci i do baze pravé plíce. Cholecystolithiasa.

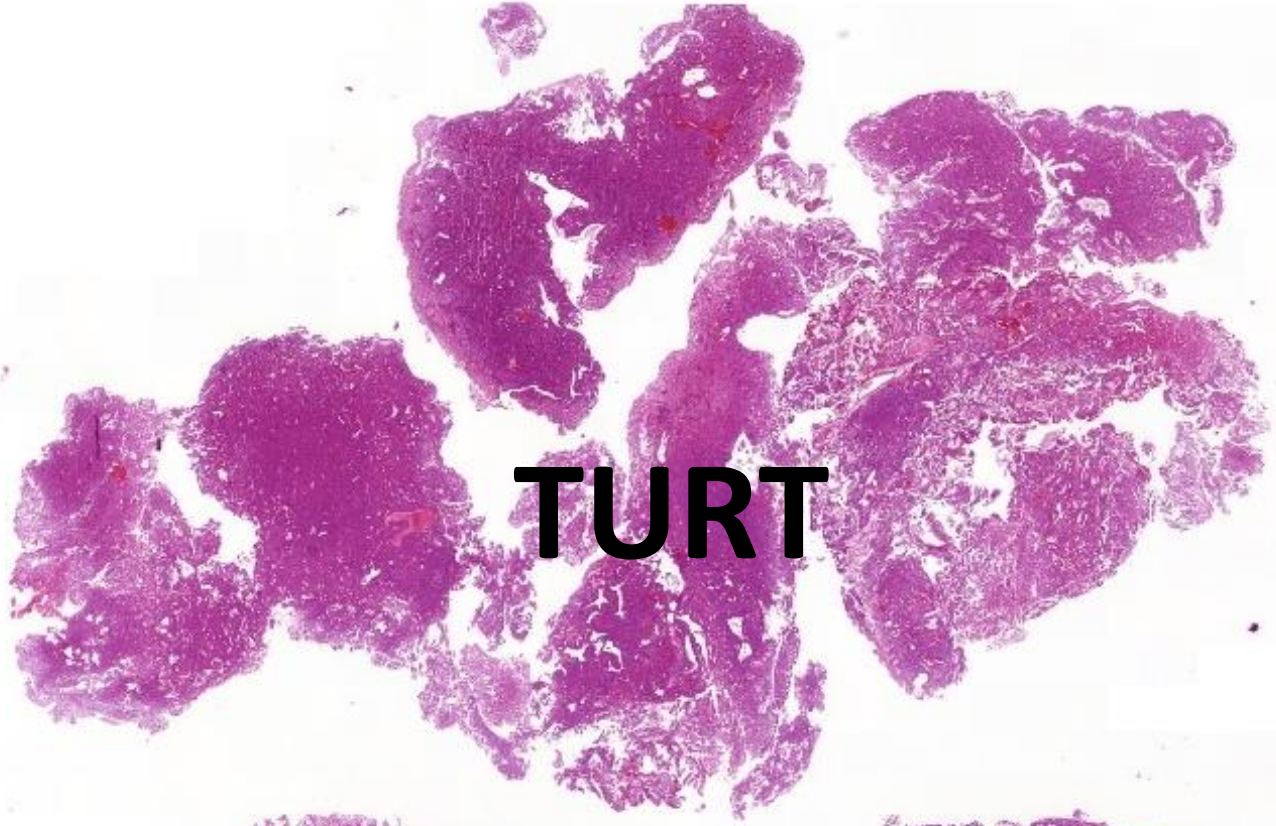

TURT

(odstraněno cca 15 g prostaty)

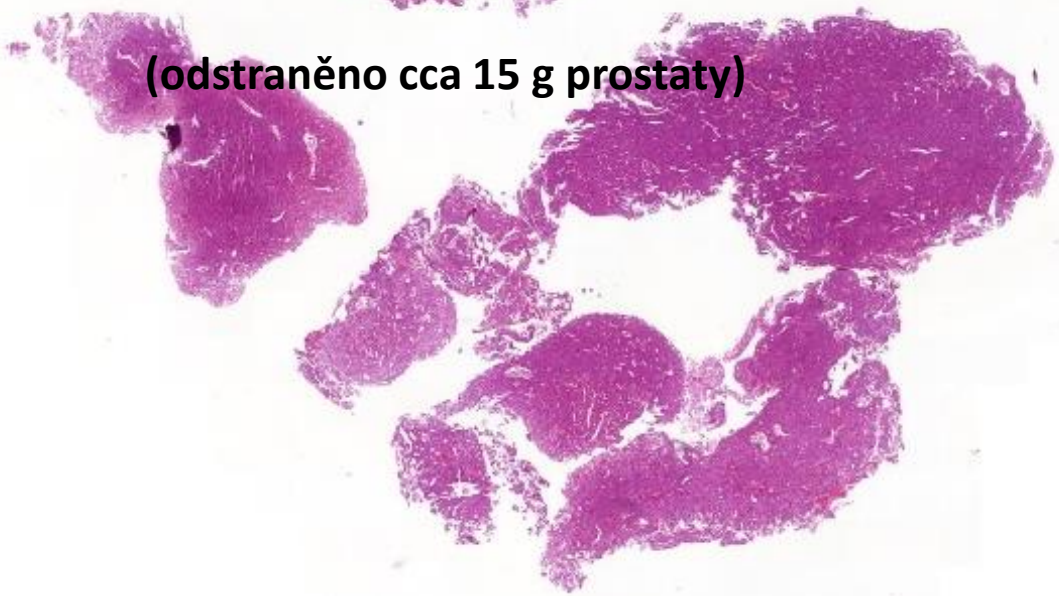

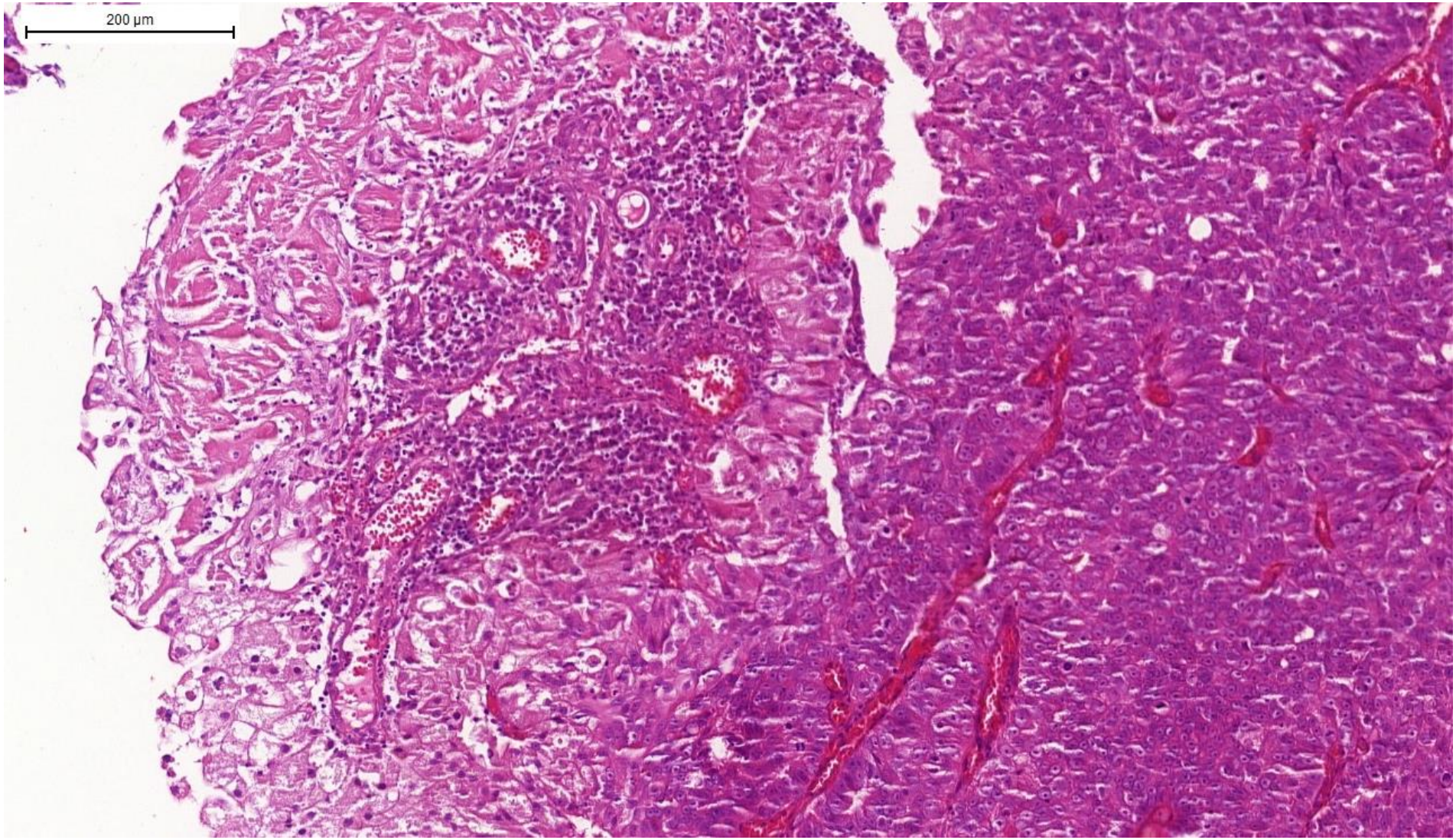
200 µm

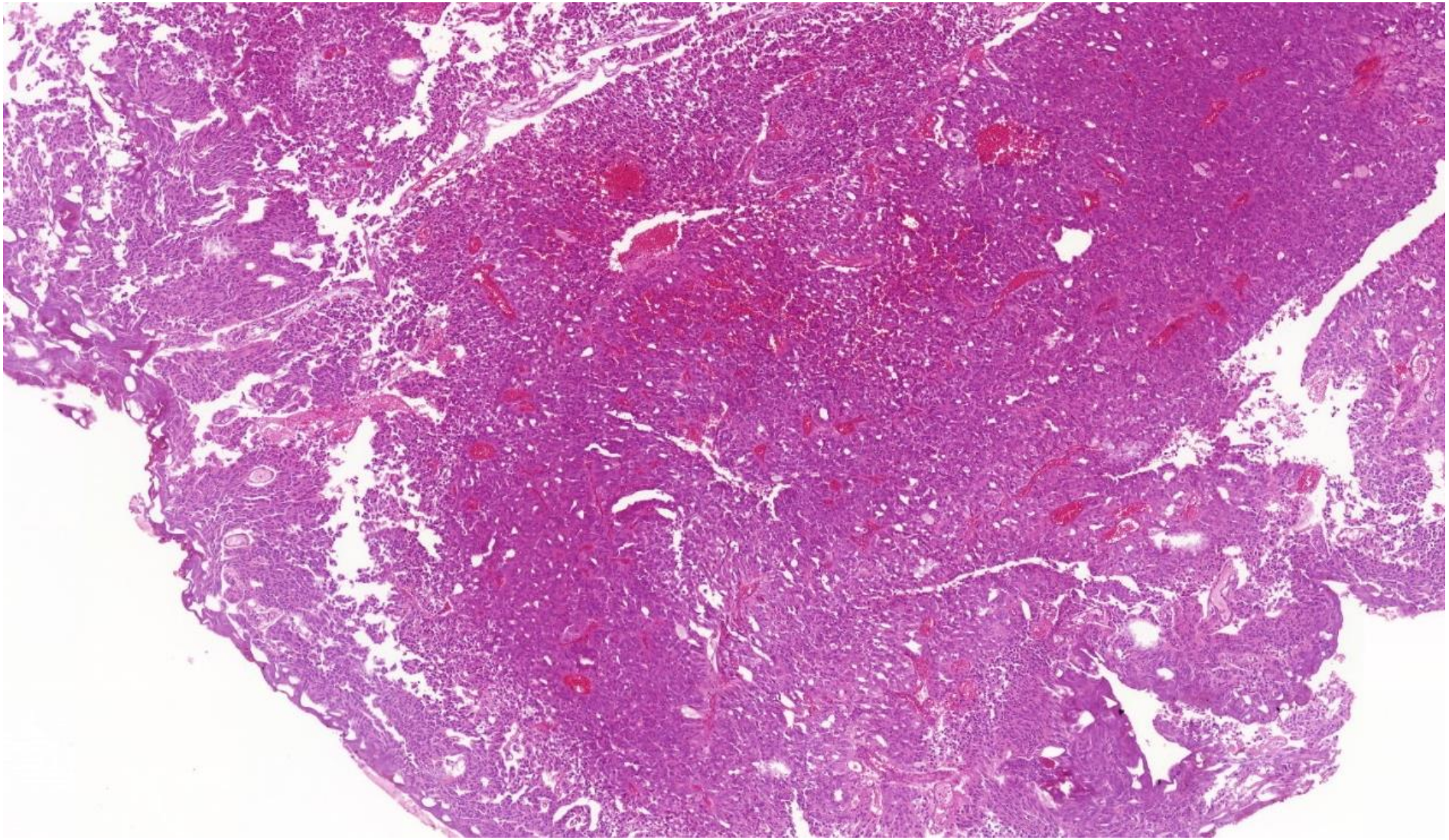

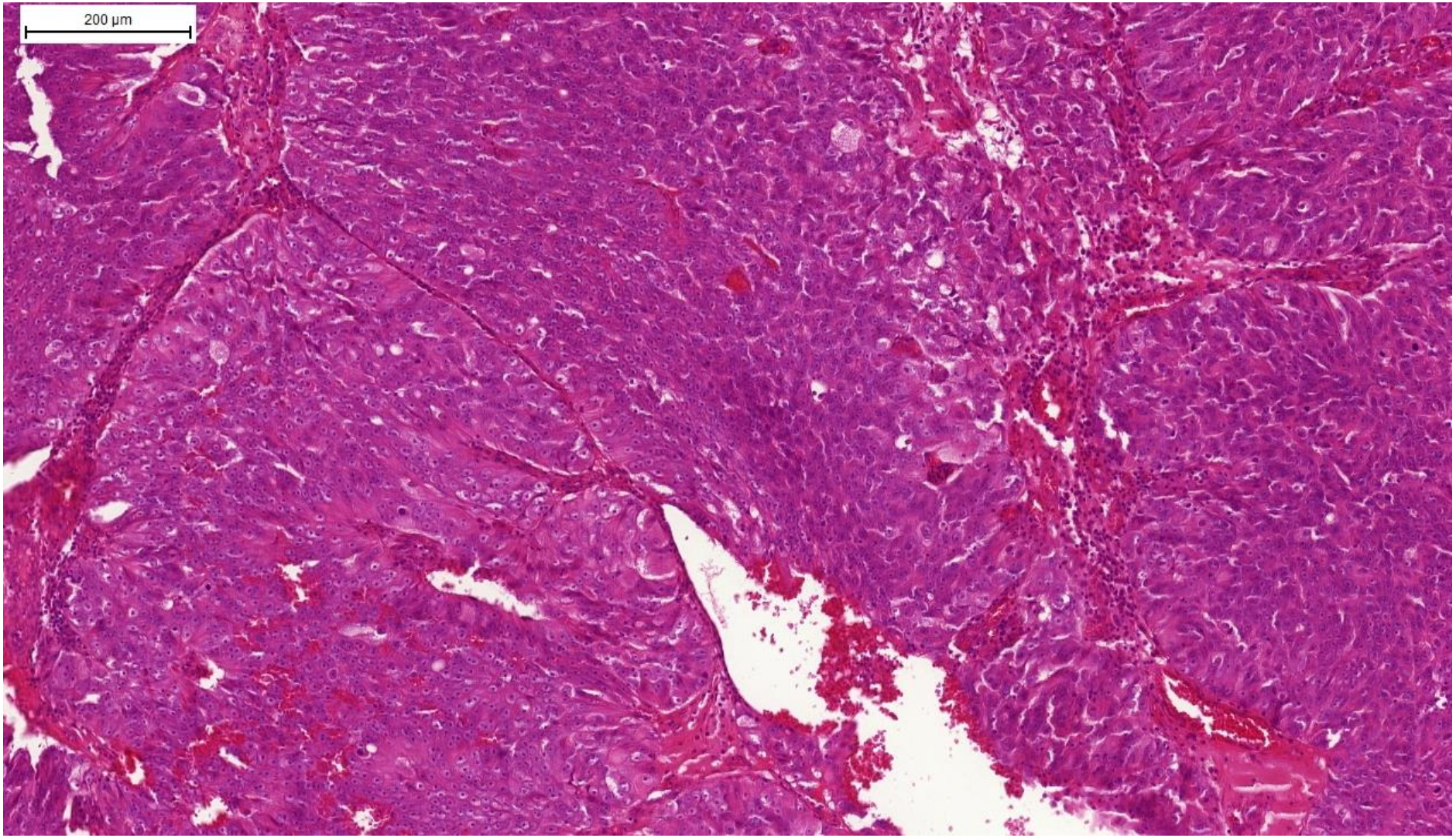
200 µm

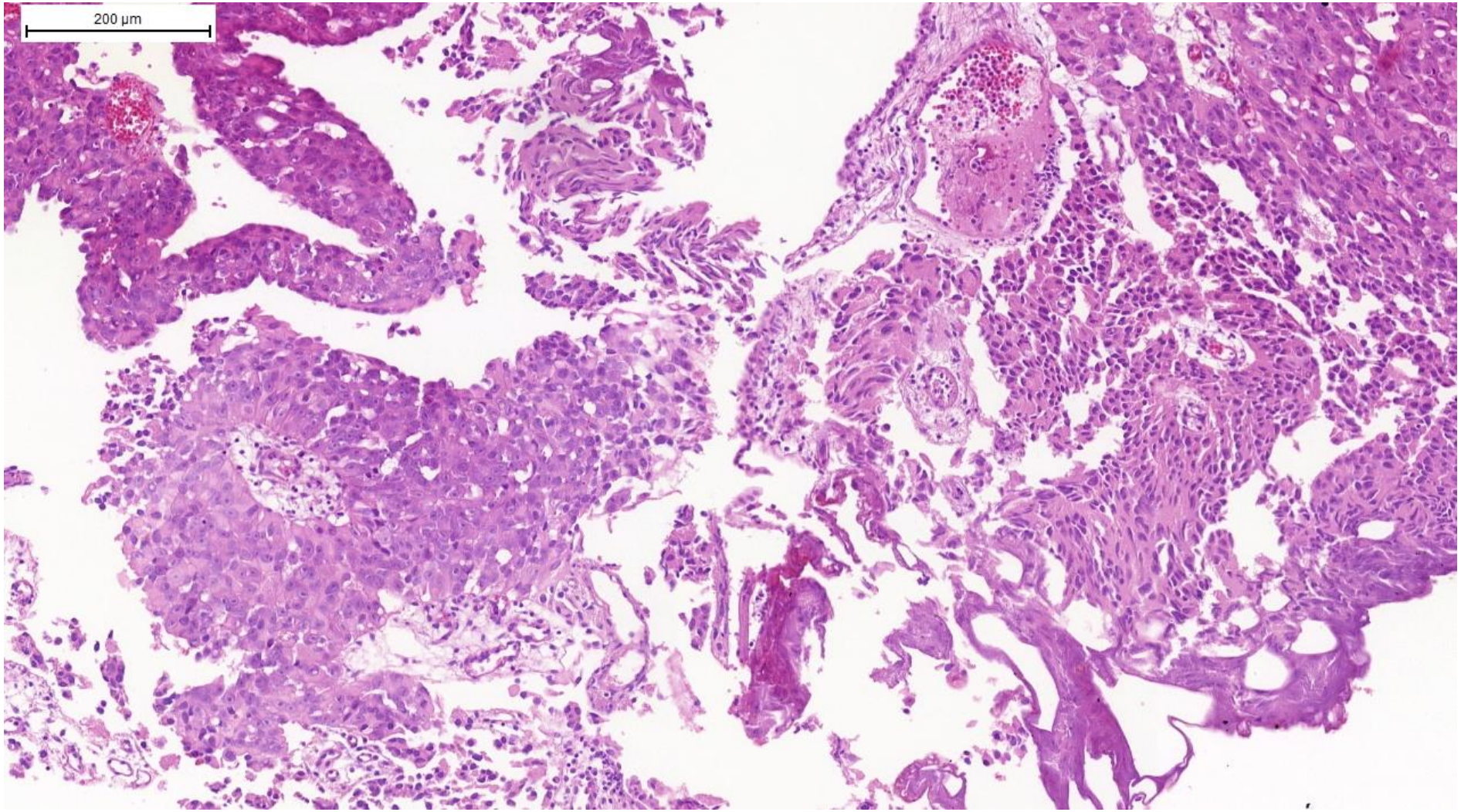
200 µm

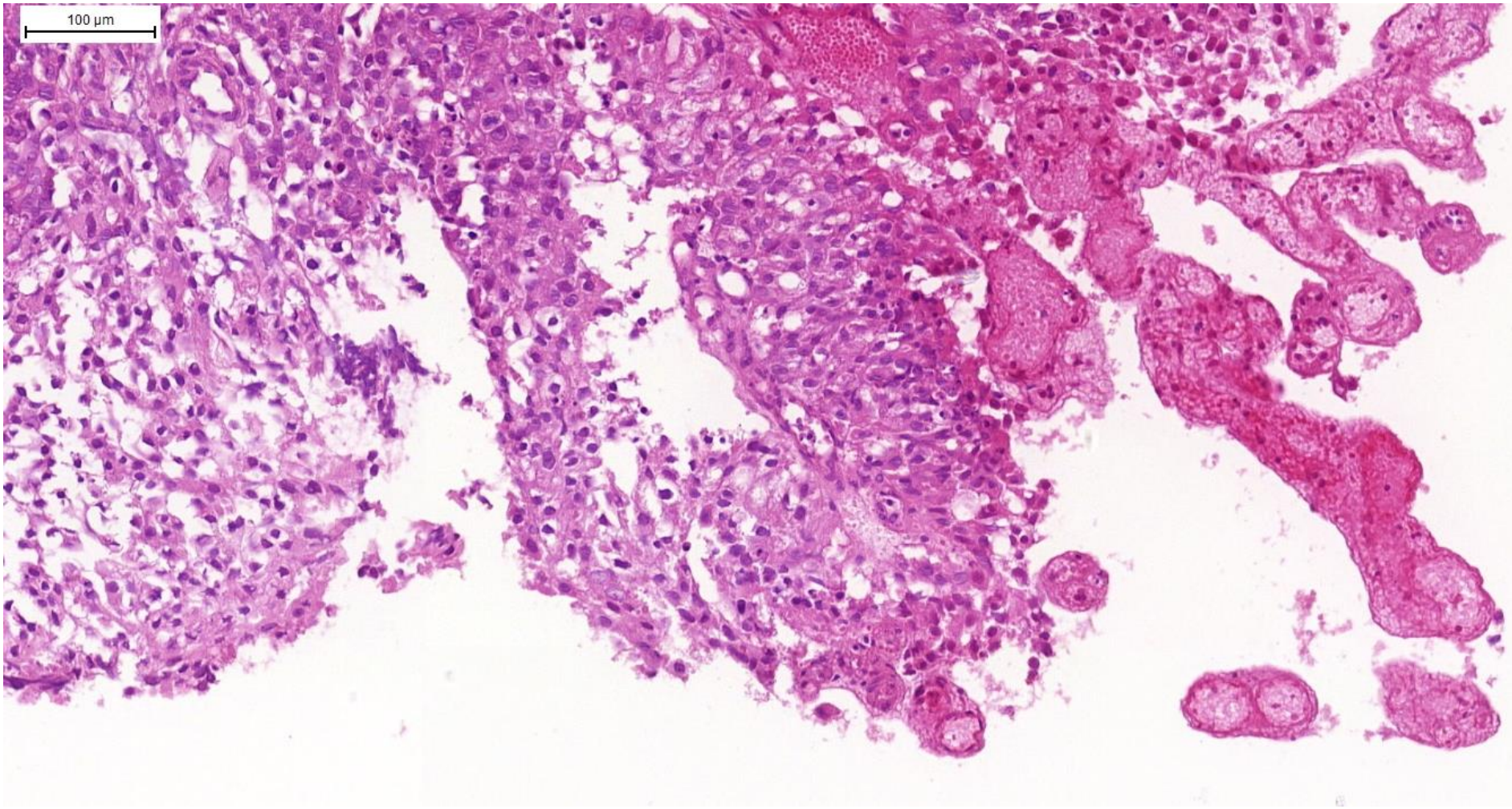
100 µm

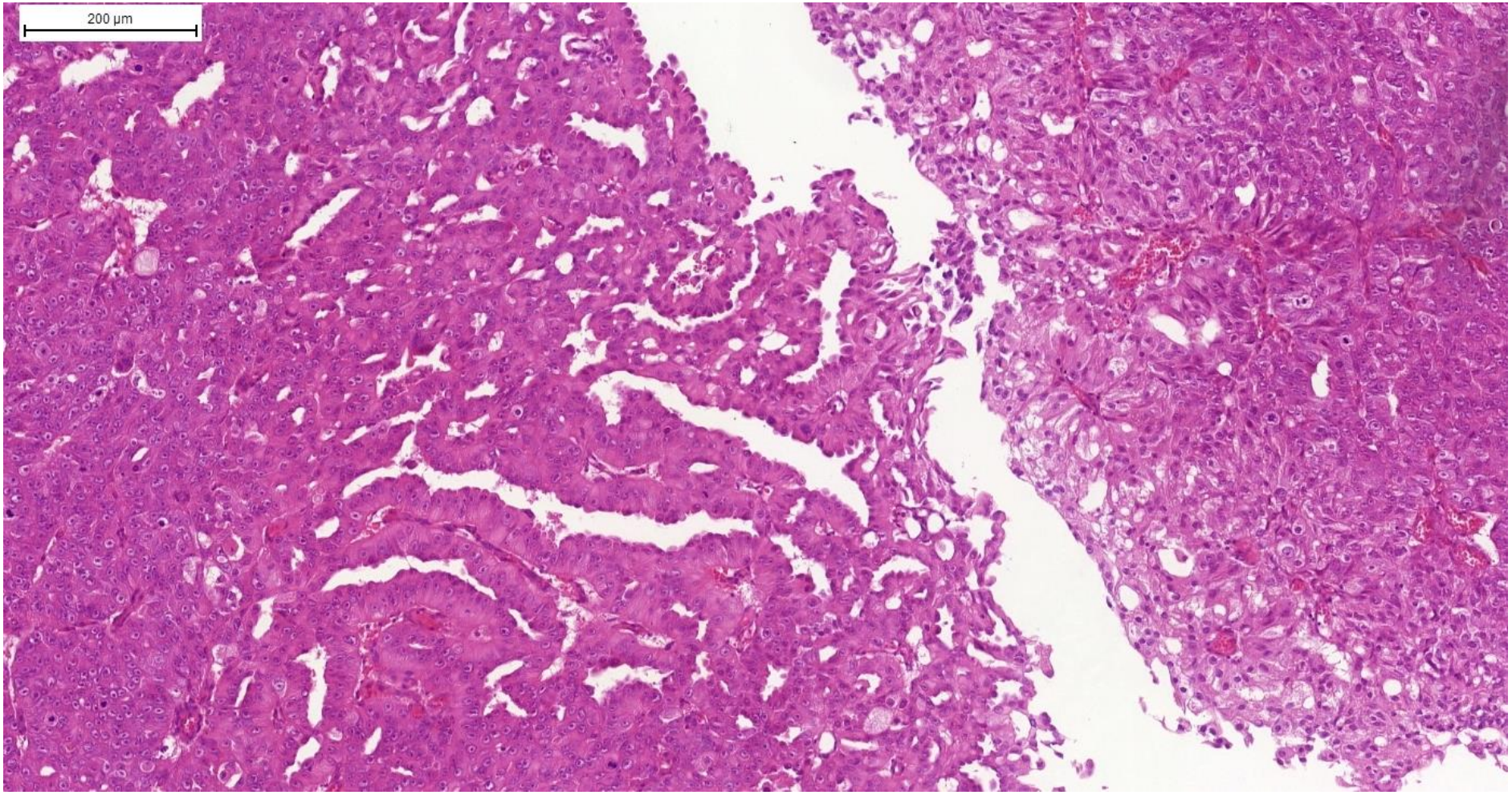
200 µm

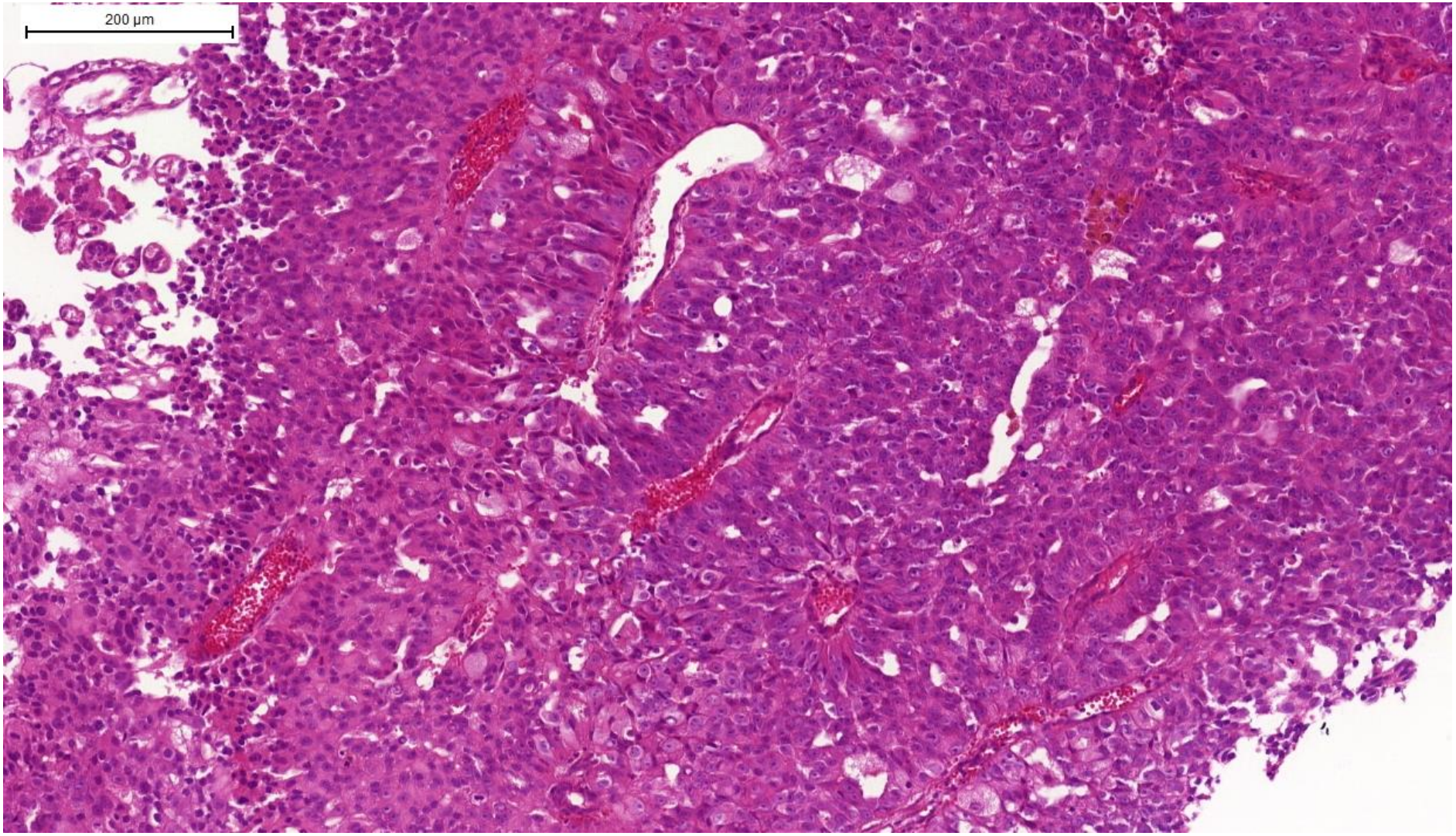
200 µm

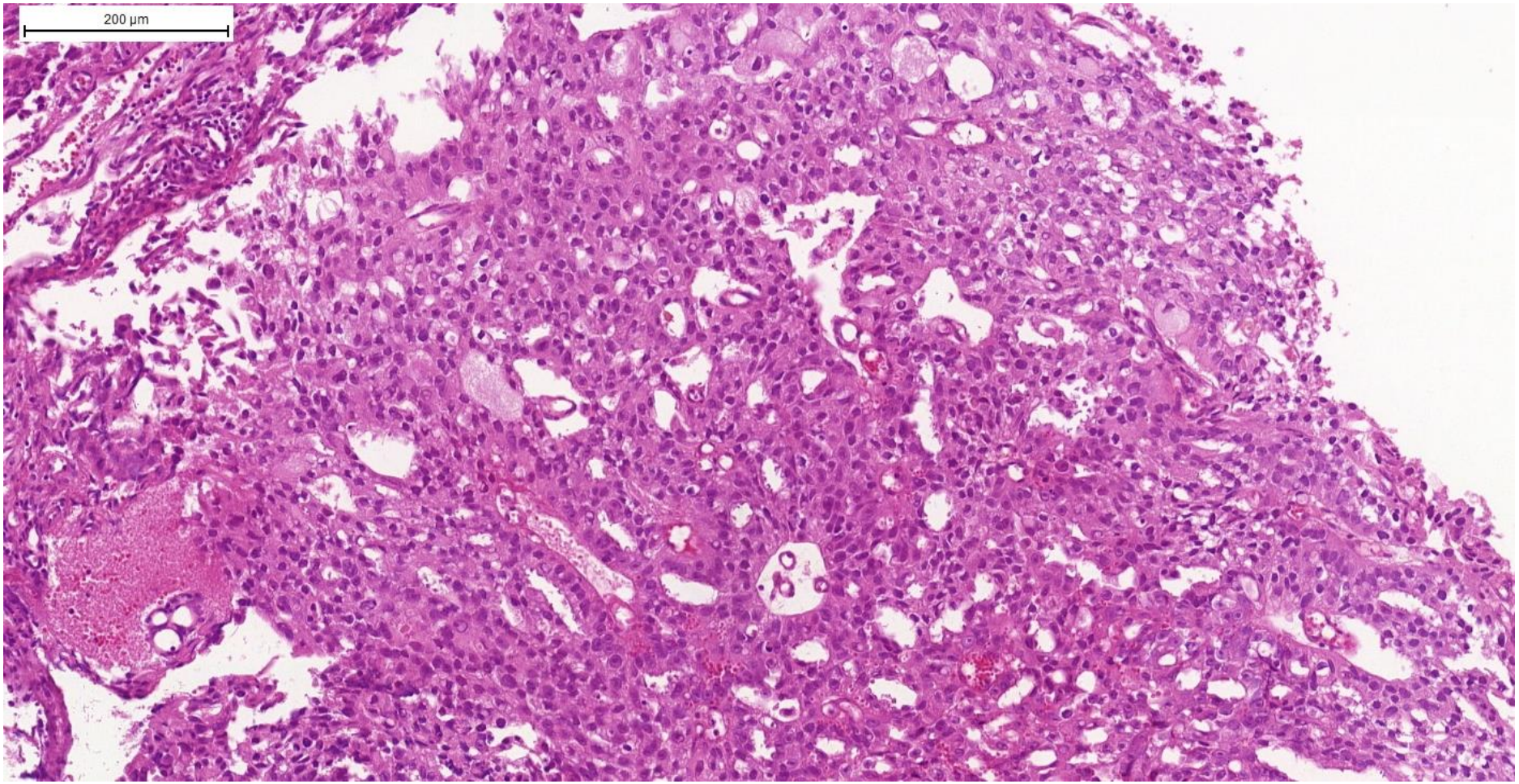
200 µm

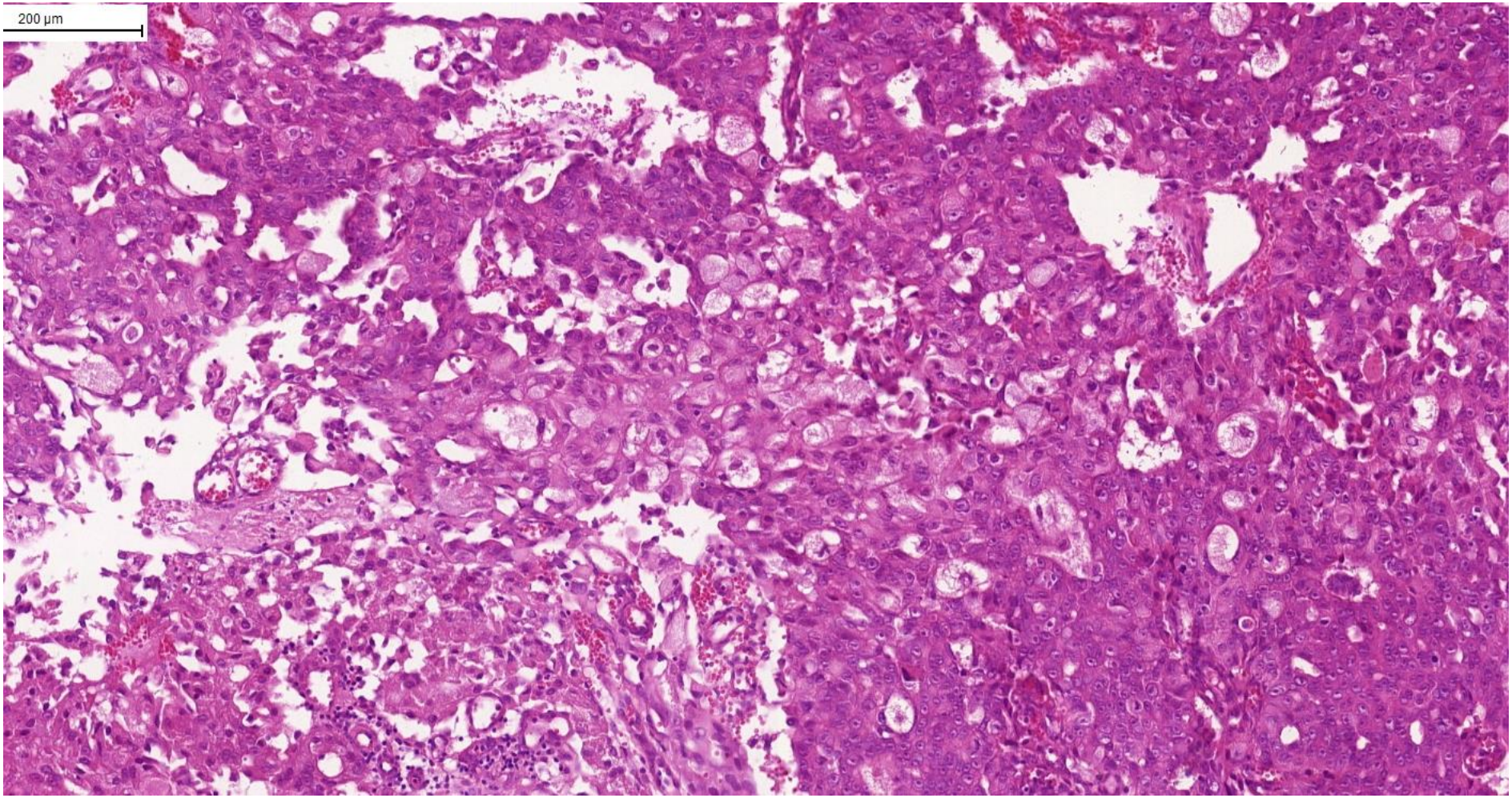
200 µm

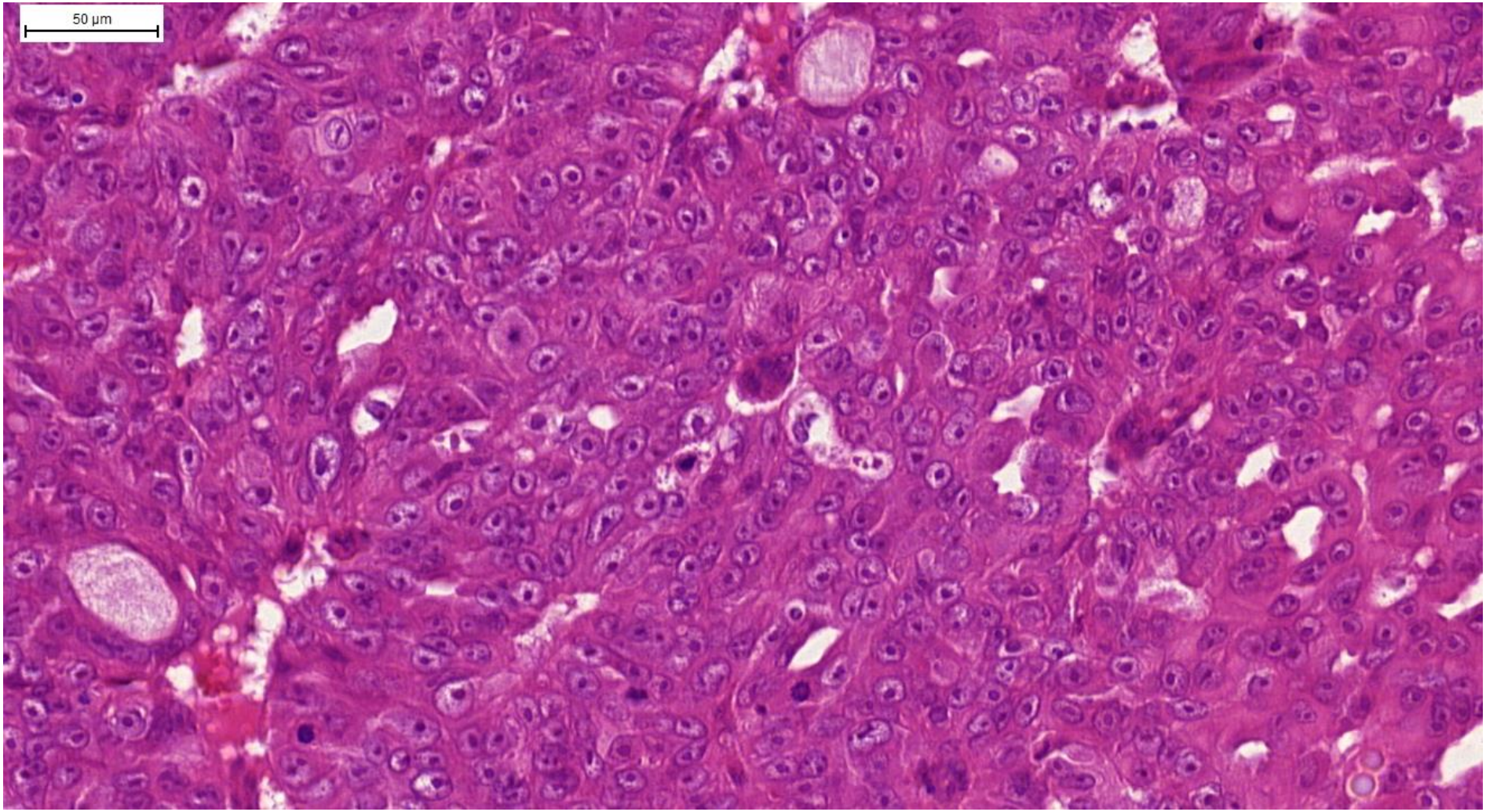
50 µm

???

CK7

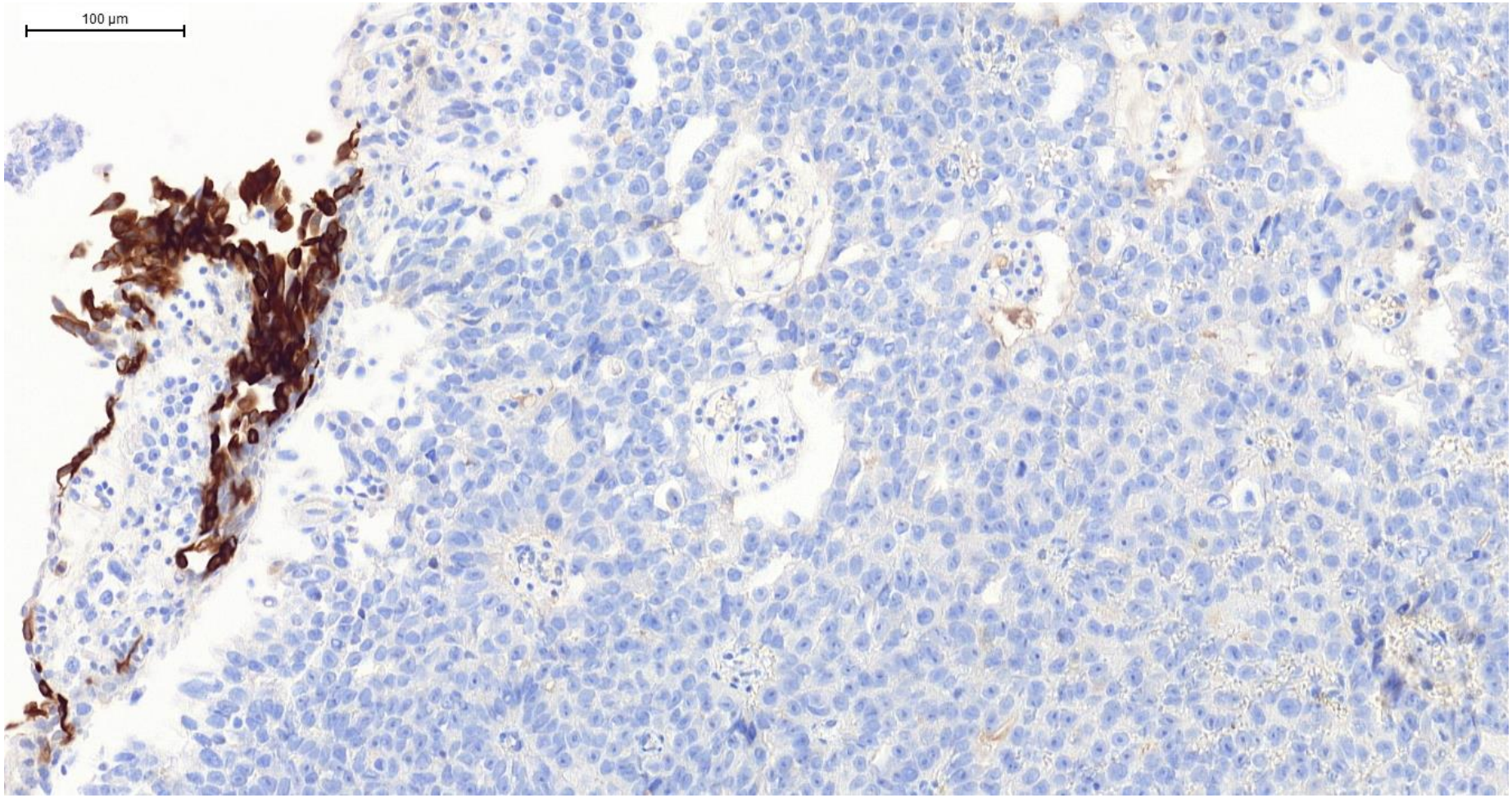

CK20

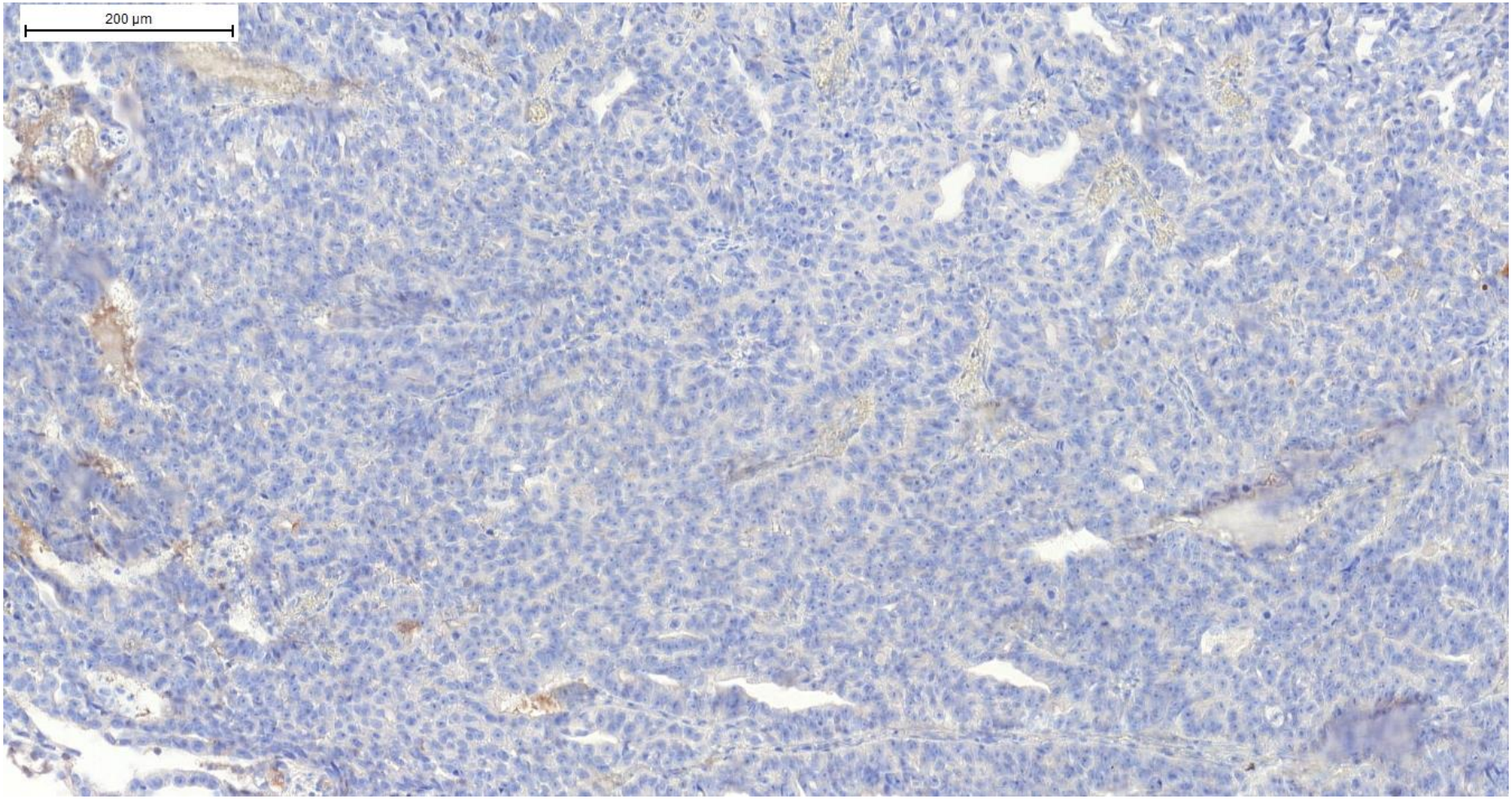

GATA 3

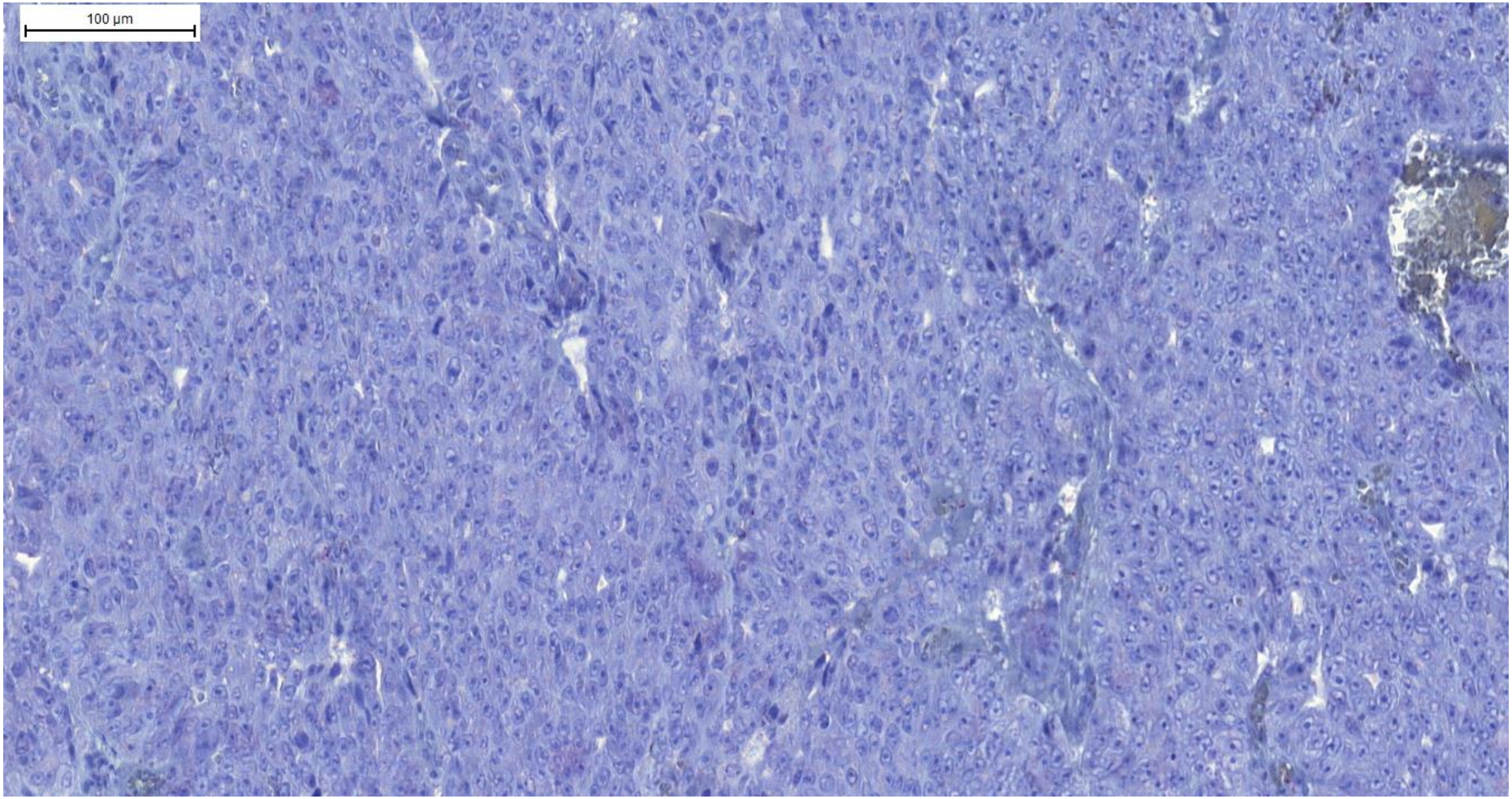

???

Datum odběru	6.8.2012 08:00	13.8.2012 12:11	28.1.2013 13:59	28.1.2013 14:00	Stav	Vývoj	Normály	Jednotky
Pozn. k odběru								
Krevní obraz								
B--Le			9,30				4 - 10	10^9/l
B--Ery			4,83				4 - 5,8	10^12/l
B--Hb			138				135 - 175	g/l
B--HTK			0,422				0,4 - 0,5	1
B--Obj ery.			88				82 - 98	fl
B--Hb ery			28,5				28 - 34	pg
B--Hb konc			326				320 - 360	g/l
B--Erytr.křivka			13,4				10 - 15,2	%
B--Trombo			269				150 - 400	10^9/l
Biochemie								
P/S--AST			0,40				0 - 0,8	ukat/l
P/S--ALT			0,26				0 - 1	ukat/l
P/S--GGT			0,59				0 - 1,9	ukat/l
P/S--Močovina			**2,5**				3 - 8	mmol/l
P/S--Kreatinin			70				70 - 110	umol/l
P/S--Kys. močová			430				210 - 450	umol/l
P/S--Sodík			141				137 - 145	mmol/l
P/S--Draslík			4,0				3,6 - 4,8	mmol/l
P/S--Chloridy			102				98 - 109	mmol/l
qS--Cl korig.			**101**				102 - 105	mmol/l
P/S--CRP			**30**				< 8	mg/l
Vyšetření moče								
U--pH		5,5					5 - 6,5	
U--Bílkovina		**1**					0 - 0	arb.j.
U--Glukóza		neg.					0 - 0	arb.j.
U--Ketolátky		neg.					0 - 0	arb.j.
U--Krev		**4**					0 - 0	arb.j.
U--Bilirubin		neg.					0 - 0	arb.j.
U--Urobilinogen		neg.					0 - 0	arb.j.
U--Leuko chem.		**4**					0 - 0	arb.j.
U--Nitrity		poz.					0 - 0	arb.j.
U--Spec.hmotnost		1,017					1,01 - 1,03	g/ml
U--Leukocyty		**755**					0 - 20	počet/ul
U--Erytrocyty		**8 149**					0 - 15	počet/ul
U--Bakterie		ojedin.						arb.j.
U--Hlen		+						arb.j.
Odhad glom.filtrace								
qS--GF-MDRD			>1,58					ml/s
Nádorové markery								
S--PSA	**11,09**			**97,24**			0 - 4,5	ug/l
S--F/T				**11,45**			20 - 99	%
S--fPSA				11,13				ug/l
S--pro PSA				570				pg/ml
S--PHI				504,94				

PSA

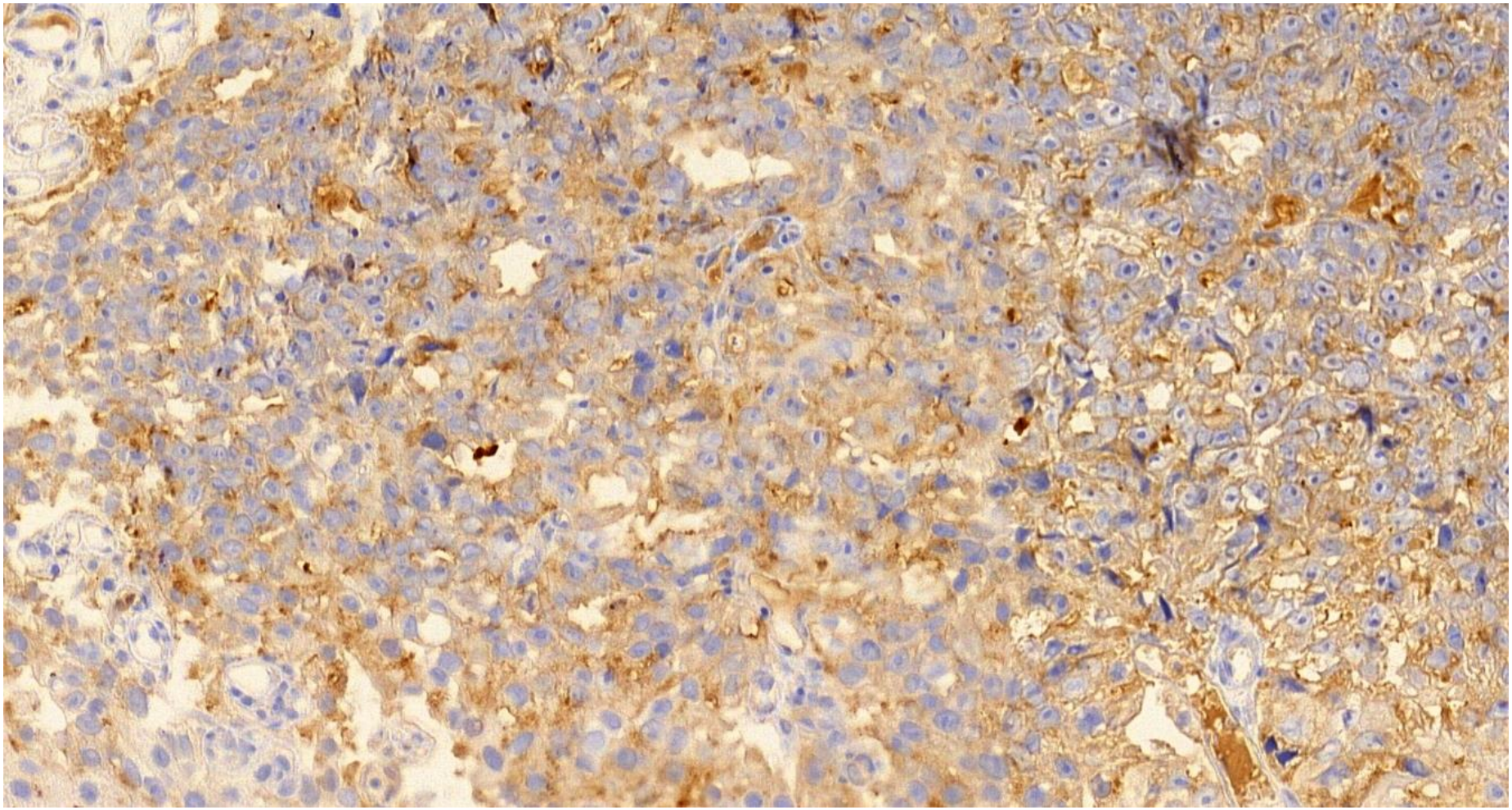

PAP

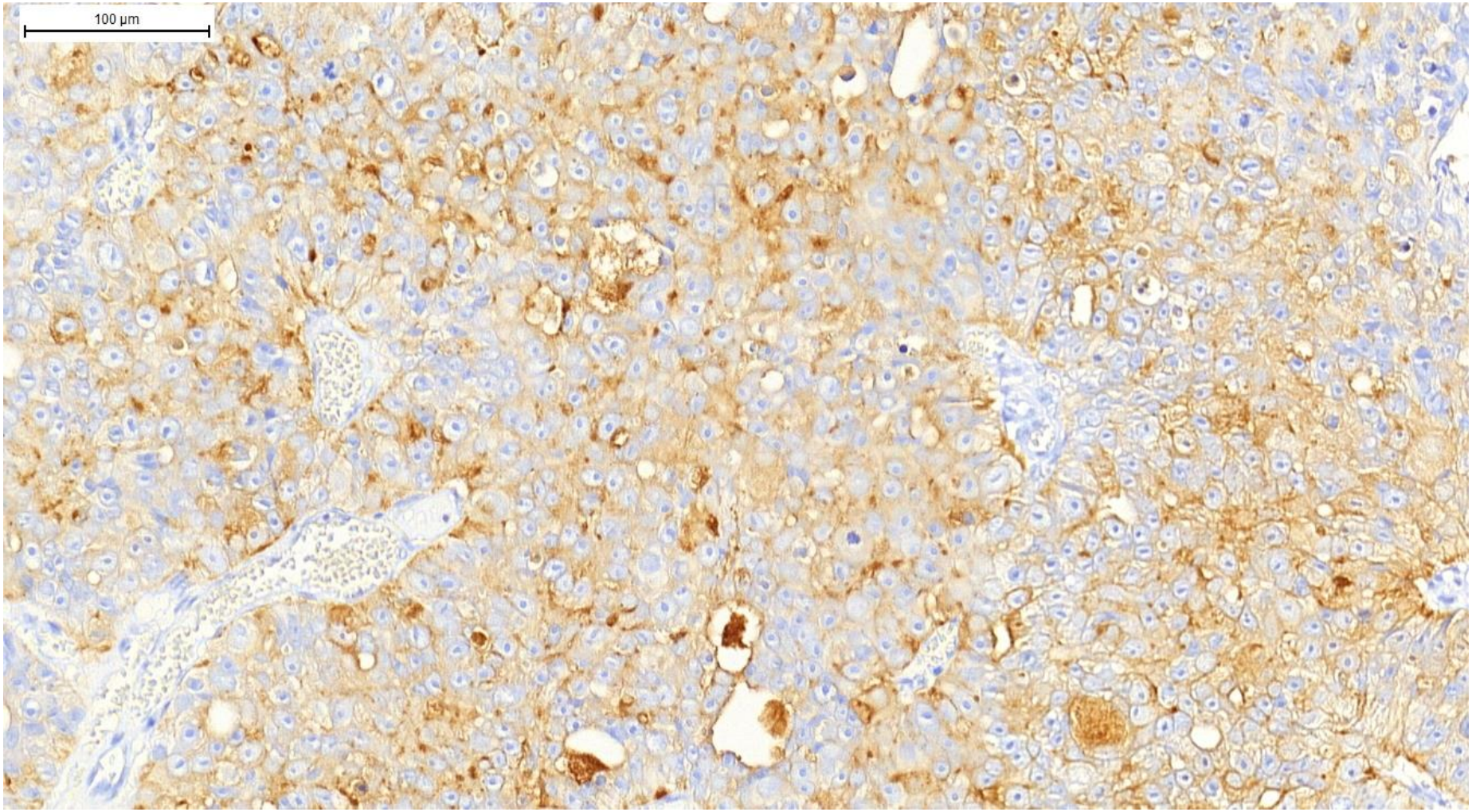

NKX3.1

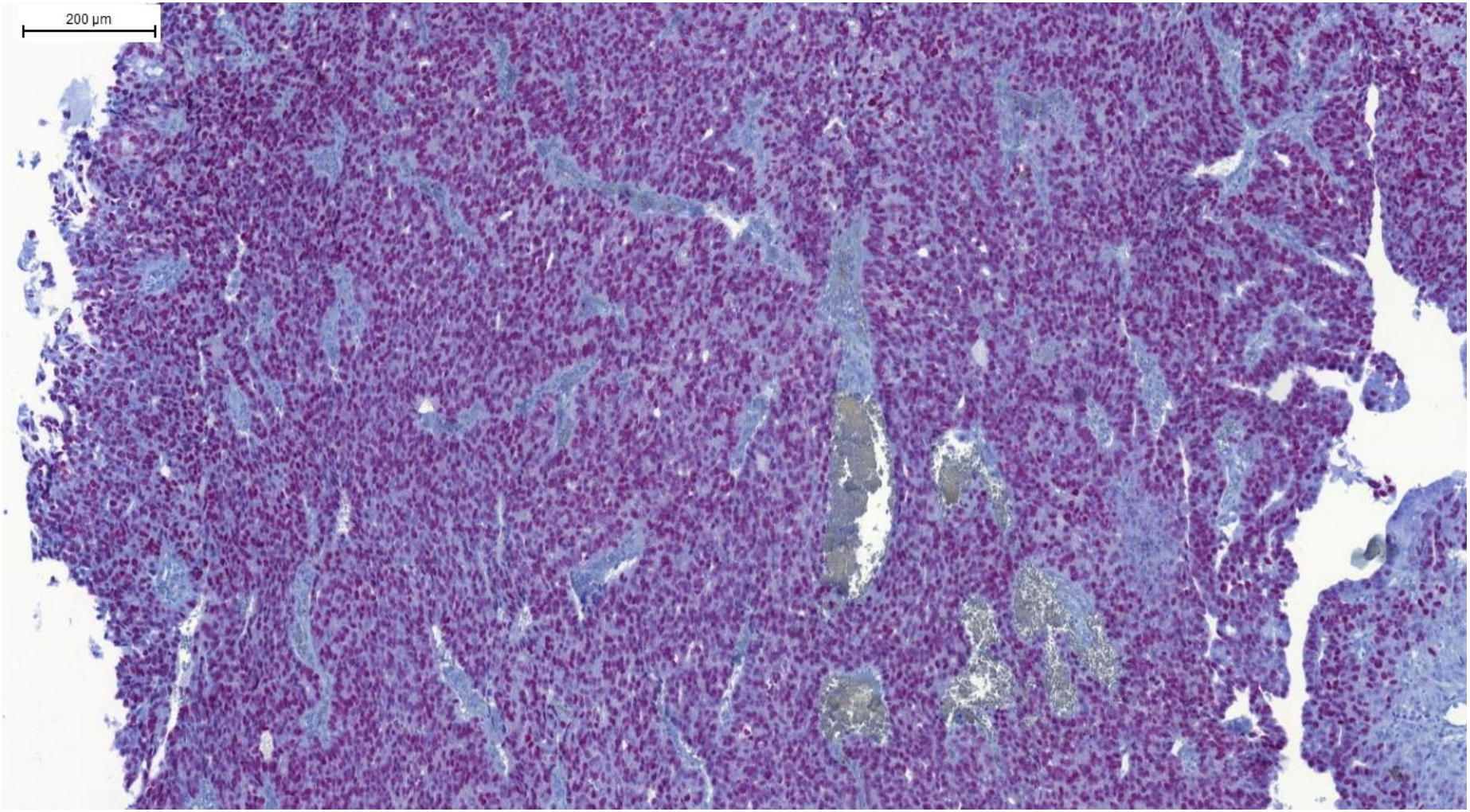

špatně diferencovaný prostatický adenokarcinom

Gleason skore 9 (4+5)

Grade group 5

Postižení močového měchýře strukturami prostatického adenokarcinomu

- prorůstání (per continuitatem – pT3a
- metastáza (M1c)

Pathological T (pT)

T Category	T Criteria
T2	Organ confined
T3	Extraprostatic extension
T3a	Extraprostatic extension (unilateral or bilateral) or microscopic invasion of bladder neck
T3b	Tumor invades seminal vesicle(s)
T4	Tumor is fixed or invades adjacent structures other than seminal vesicles such as external sphincter, rectum, bladder, levator muscles, and/or pelvic wall

Note: There is no pathological T1 classification.
Note: Positive surgical margin should be indicated by an R1 descriptor, indicating residual microscopic disease.

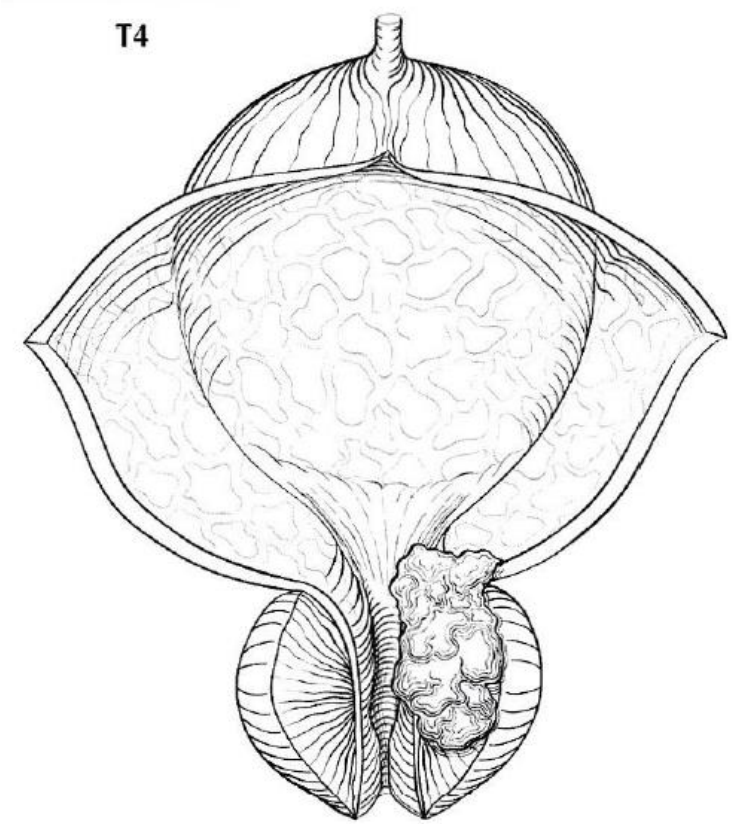

Fig. 58.9 Clinical and pathological T4 is defined as a tumor that is fixed or invades adjacent structures other than seminal vesicles such as bladder, as shown here, external sphincter, rectum, levator muscles, and/or pelvic wall

- High grade prostatický adenokarcinom (PCa) může mít obdobnou morfologii jako high grade uroteliální karcinom (UCa)

- Terapie!

- V literatuře „prostatic adenocarcinoma mimicking urothelial carcinoma“ – poprvé popsán v roce 2002 (Mai et al.)

Morfologické znaky

- UCa
  - současná přítomnost papilární uroteliální neoplasie či ploché léze,
  - výrazná jaderná pleomorfie,
  - eosinofilní cytoplasma,
  - briskní mitotická aktivita

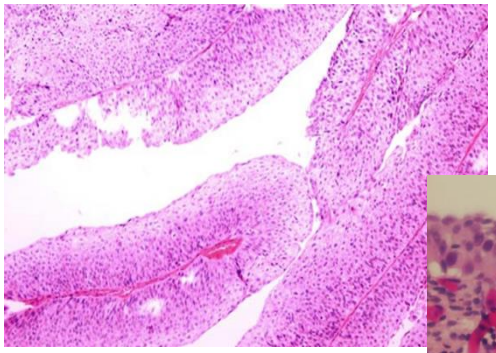

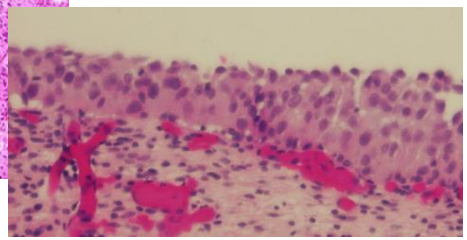

- PCa
  - acinární či kribriformní architektonika,
  - minimální jaderný pleomorfismus,
  - prominentní jadérka,
  - foamy až světlá cytoplasma,
  - nižší mitotická aktivita

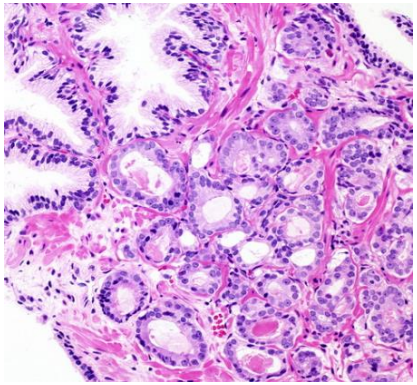

Pseudopapillary Features in Prostatic Adenocarcinoma Mimicking Urothelial Carcinoma

A Diagnostic Pitfall

Jennifer Gordetsky, MD and Jonathan I. Epstein, MD*†‡*

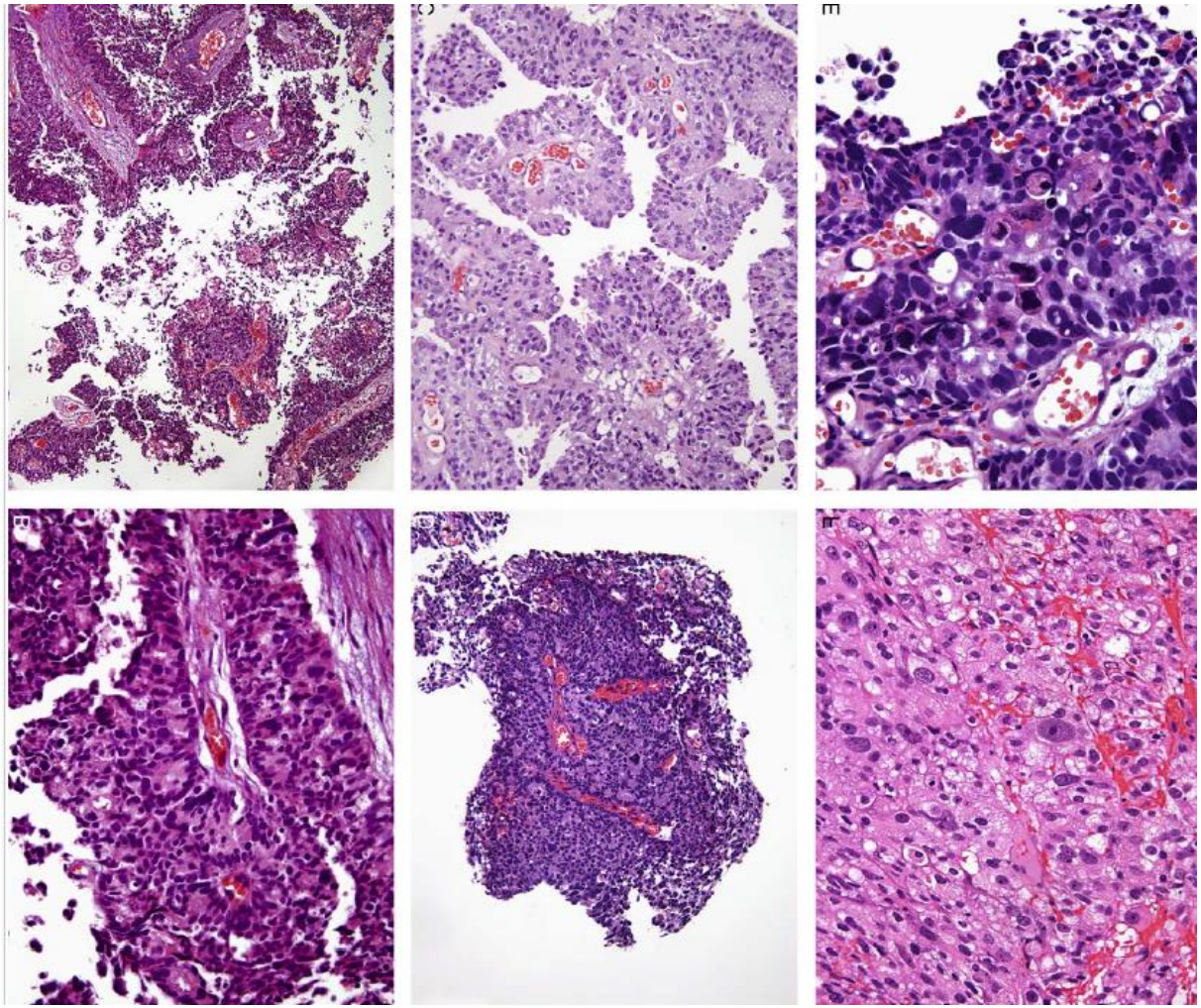

AJSP 2014; 38: 941-945

IHC

UCa	PCa
• CK7 • CK20 • GATA3 • Uroplakin III • Uroplakin II • p63 • HMWCK (K903, CK5/6) • S100P	• PSA • PAP • NKX3.1 • Prostein (p501S) • PSMA

IHC

UCa	PCa
• CK7 • CK20 • GATA3 • Uroplakin III • Uroplakin II • p63 • HMWCK (K903, CK5/6) • S100P	• PSA • PAP • NKX3.1 • Prostein (p501S) • PSMA

IHC

UCa	PCa
• CK7 • CK20 • GATA3 • Uroplakin III • Uroplakin II • p63 • HMWCK (K903, CK5/6) • S100P	• PSA • PAP • NKX3.1 • Prostein (p501S) • PSMA

IHC

UCa	PCa
• CK7 • CK20 • GATA3 • Uroplakin III • Uroplakin II • p63 • HMWCK (K903, CK5/6) • S100P	• PSA • PAP • NKX3.1 • Prostein (p501S) • PSMA

IHC

ISUP Recommendations

(1) Option to ***use PSA as a first test to identify PCa and GATA3 to identify UC***.

(2) If GATA3 is not available, then HMWCK and p63 can be used.

(3) If the tumor is PSA positive with intense staining and HMWCK and p63 negative, the findings are diagnostic of PCa.

(4) If the tumor is equivocal/weak/negative for PSA and negative/focal for p63 and HMWCK, then staining for P501S, NKX3.1, and GATA3 must be performed.

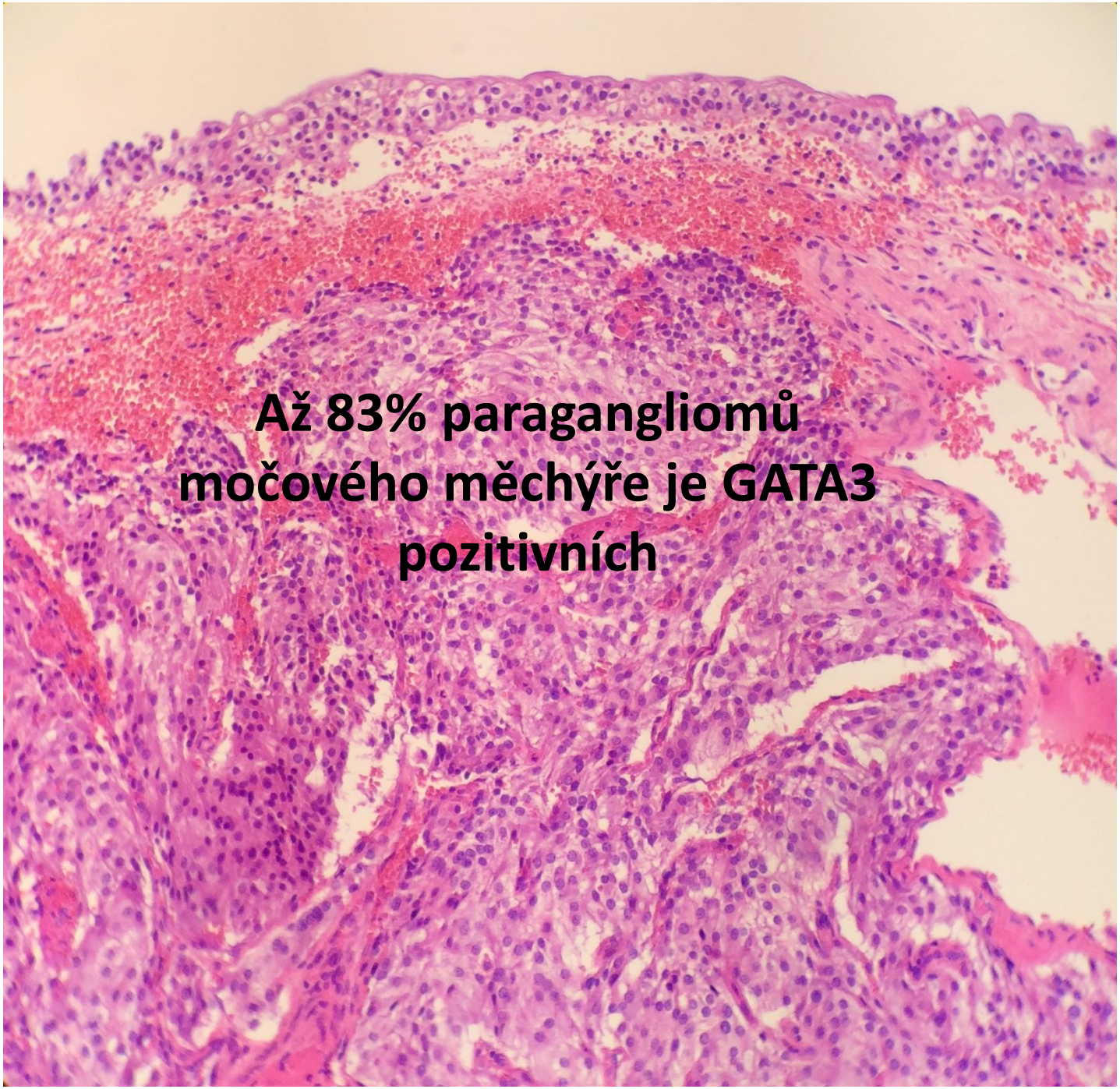
Až 83% paragangliomů
močového měchýře je GATA3
pozitivních

… zpět k pacientovi …

- Nízce diferencovaný adenokarcinom prostaty s rozsáhlou infiltrací močového měchýře, s generalizací do skeletu, s podezřením na generalizaci do plic T4 N0M1, GS 9 (5+4), PSA 97, poměr 11,45; PHI 504 (2/2013 urolog. klin. FN Plzeň)
- Kompletní androgenní blokáda od 3/2013 - 3/2014 s přechodným poklesem PSA na 34,02 (urolog. klin. FN Plzeň)
- Progrese onemocnění významně lokálně a ve skeletu, susp. solit. meta v plíci, elevace PSA na 94,22 k 3/2014
- Stav po 1.-5 serii Docetaxel s Prednisonem (3-8/14 ORAK) - ukončeno pro progresi PSA na 848 v 8/14
- Paliativní chemoterapie Jevtana (9/14 – 1/2015 ORAK) - ukončeno pro poruchy krvetvorby
- Stav po nedokončeném paliativním ozáření prostaty (1/2015 ORAK)
- Symptomatická terapie v terminálním stádiu - analgetika, infuze (2/2015 ORAK)
- Umírá (2/2015 ORAK)

Best Practices Recommendations in the Application of Immunohistochemistry in the Bladder Lesions

Report From the International Society of Urologic Pathology Consensus Conference

Mahul B. Amin, MD, Kiril Trpkov, MD,† Antonio Lopez-Beltran, MD,‡ David Grignon, MD,§ and Members of the ISUP Immunohistochemistry in Diagnostic Urologic Pathology Group*

AJSP 2014; 38: e20-e34

Best Practices Recommendations in the Application of Immunohistochemistry in the Prostate

Report From the International Society of Urologic Pathology Consensus Conference

Jonathan I. Epstein, MD, Lars Egevad, MD, PhD,† Peter A. Humphrey, MD, PhD,‡ Rodolfo Montironi, MD,§ and Members of the ISUP Immunohistochemistry in Diagnostic Urologic Pathology Group*

AJSP 2014; 38: e6-e19

Děkuji za pozornost!